

# Orthovoltage radiotherapy for NMSC and benign conditions

April 2026  
SOCHIRA, Chile

Dr Richard Shaffer

# Current roles

- Private Practice - Radiation Oncologist
  - Benign MSK, skin cancer
- Xstrahl - Medical Director
- RT-ABC - CEO
- IORBC – President
- Theralife – Medical Director

# Why Orthovoltage – Easy clinical pathway

## Simple

No shell or immobilisation

No bolus

Standard lead cutouts (most)

## Quick

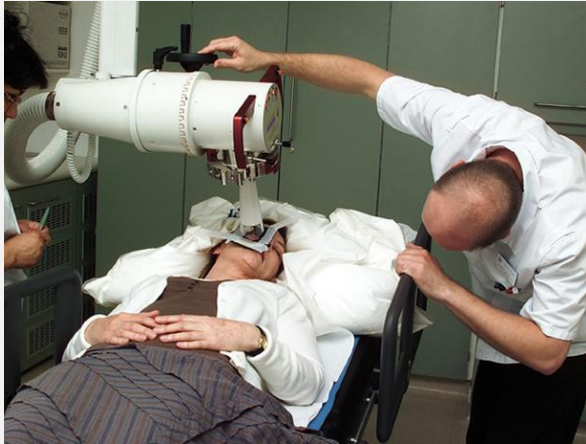Single visit for:

*Markup + first fraction*

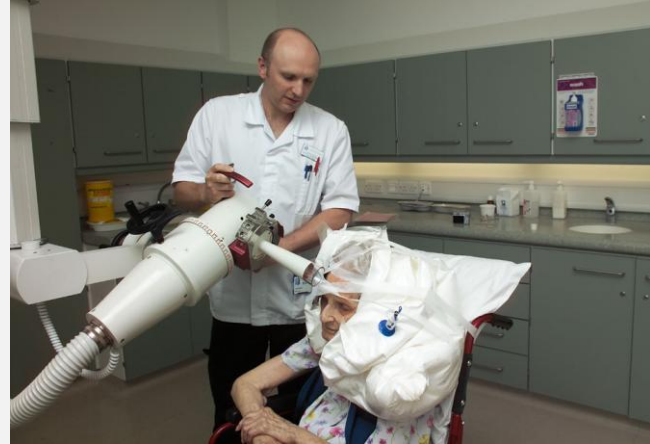Short treatments

*5 - 15 mins*

# Why Orthovoltage - Comfort



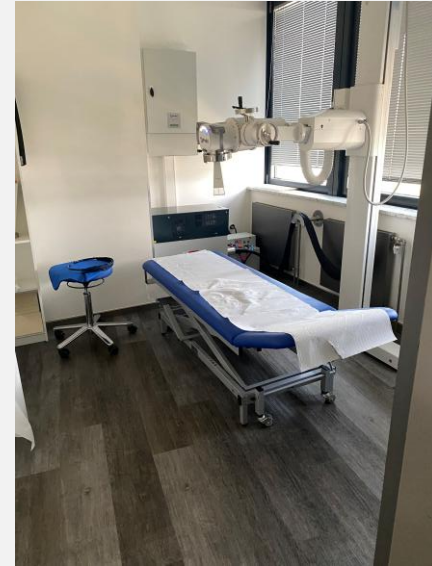Soft couch  
-  
Pillows



Wheelchair  
-  
Bed

# Why Orthovoltage - Value

- Low capital requirement
- Reduces LINAC workload
- Small footprint
  - Dual-modality room with HDR brachy, CT sim etc.
- Low shielding requirement
  - 2 – 20 mm lead
- Low per-case consumable cost



# Clinical Use

1. \*Skin cancer
2. Benign (MSK, soft tissue)
3. Palliative (bone, soft tissue)

# Non-Melanoma Skin Cancer: The challenge

- Most common cancer worldwide
- Increasing incidence
- Under-estimated in registries
- Low mortality but high morbidity

# NMSC: Treatment Options

- Dermatological
  - Curettage and electrodesiccation (C&E)
  - Photodynamic therapy (PDT)
  - Topical (imiquimod, 5FU, diclofenac)
- Surgical
  - Simple excision
  - Moh's surgery
- Radiotherapy

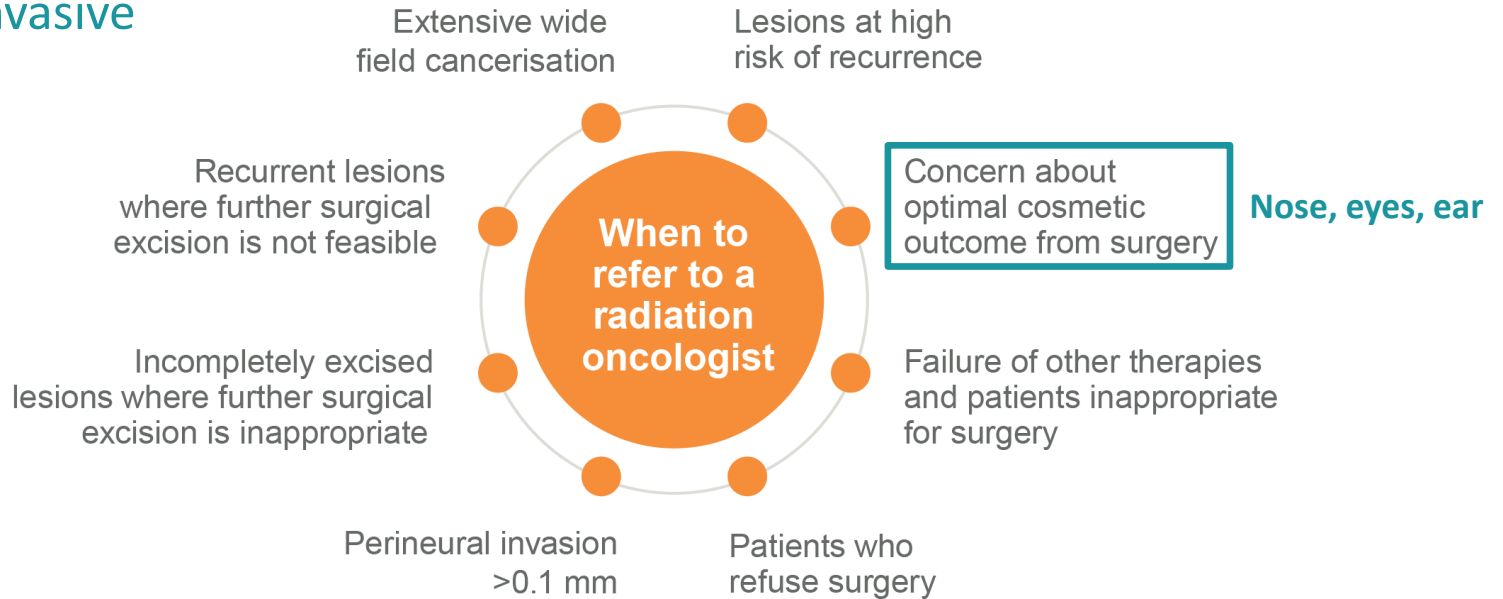
# NMSC: Treatment Decisions

- Tend to depend on
    - Established referral pathways
    - Clinician preference and awareness of options
    - Expertise of clinician
  - Does not give patients full choice
- 
- Either RT not considered
  - Or RT only for advanced cases or frail patients

# Radiotherapy Indications

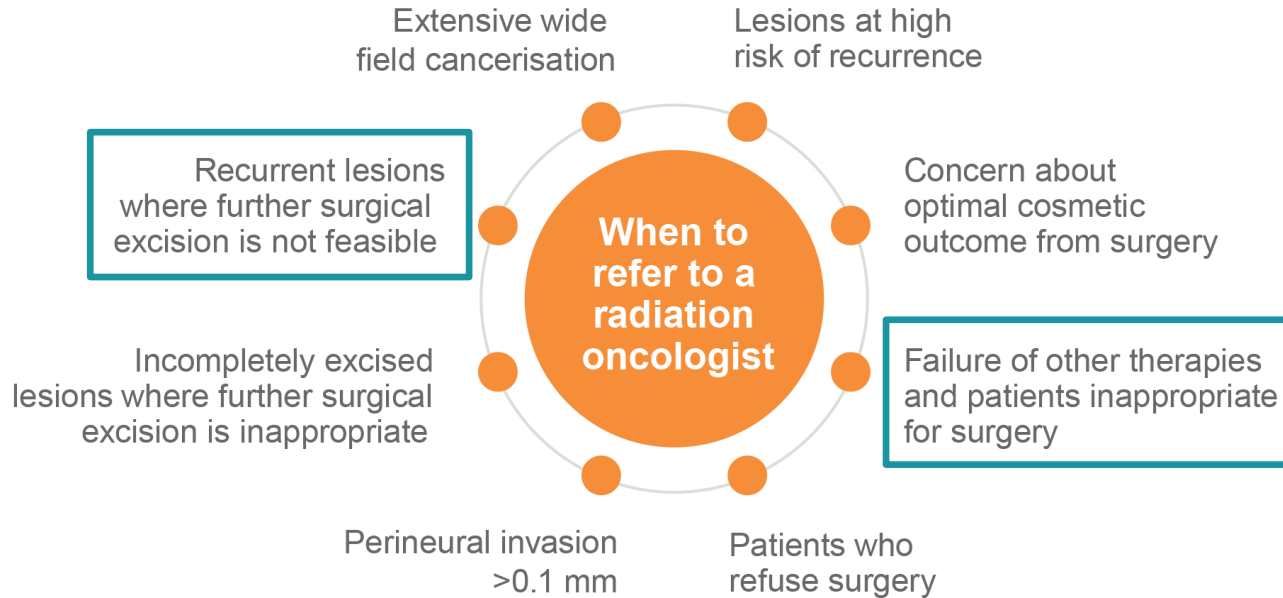
## Patient choice

- Cosmesis
- Non-invasive



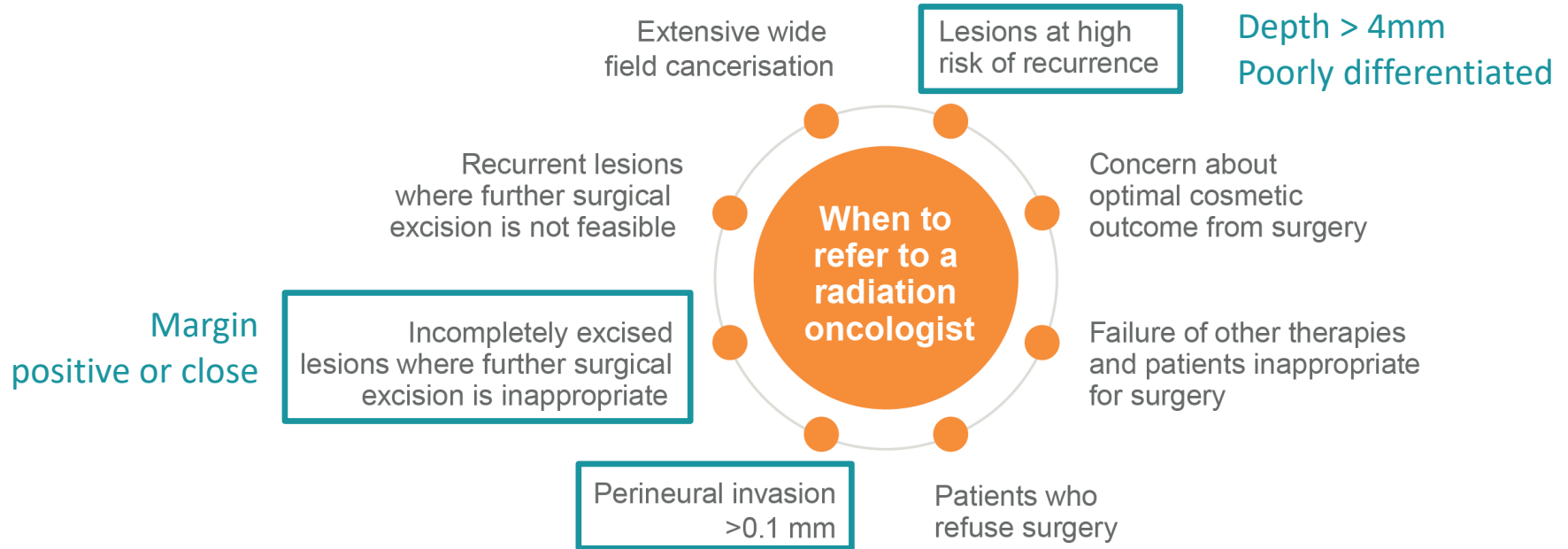
# Radiotherapy Indications

## Surgery not possible or refused

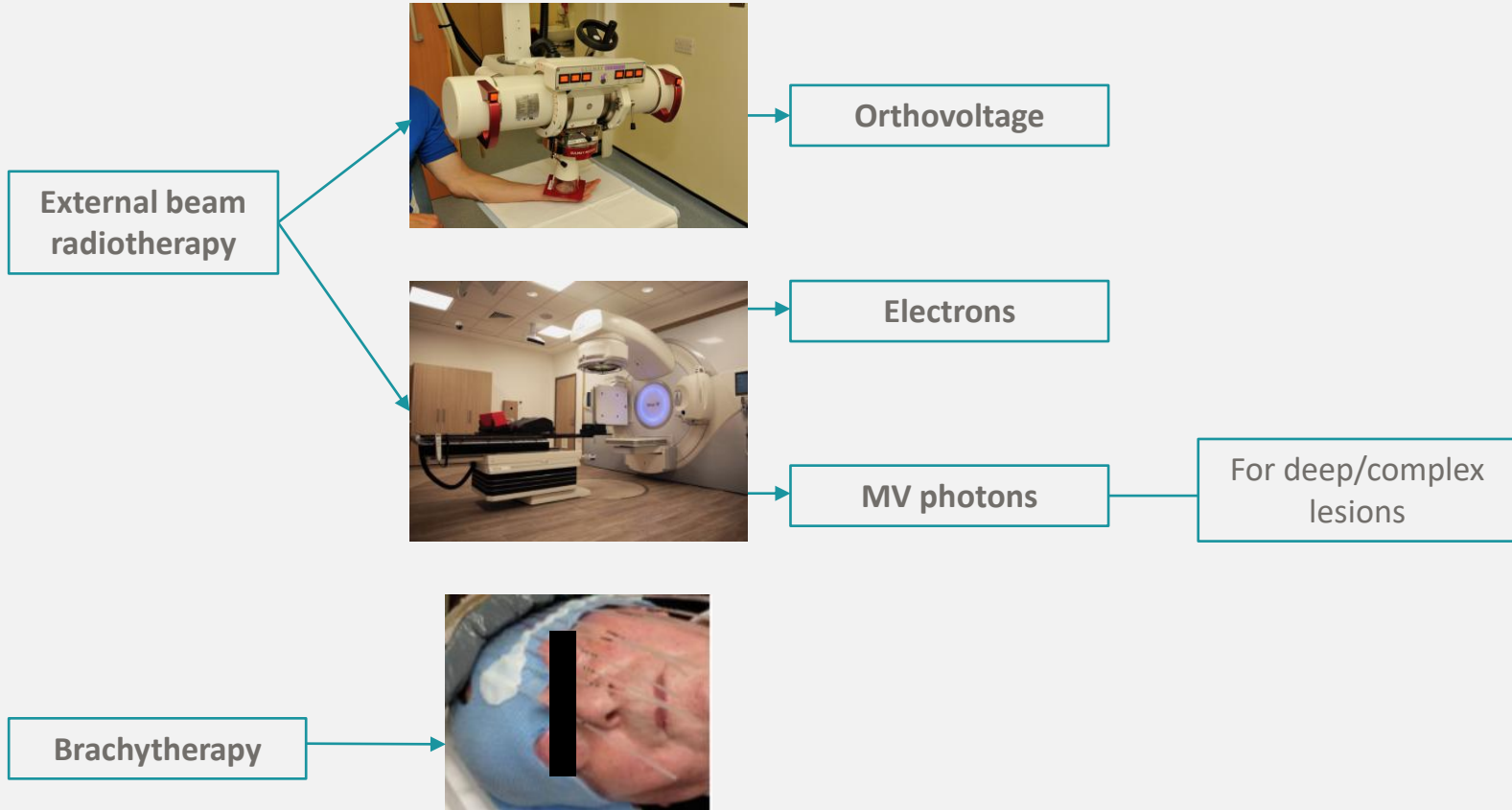


# Radiotherapy Indications

## High risk post-operative features



# NMSC: Radiotherapy modalities



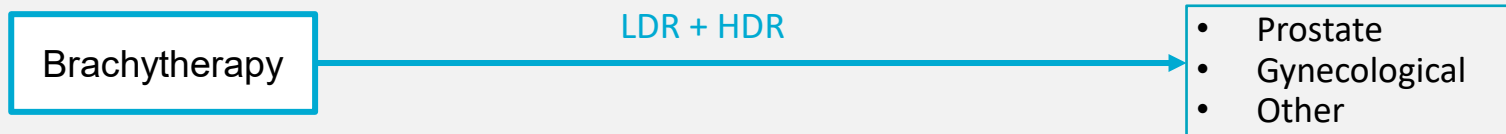
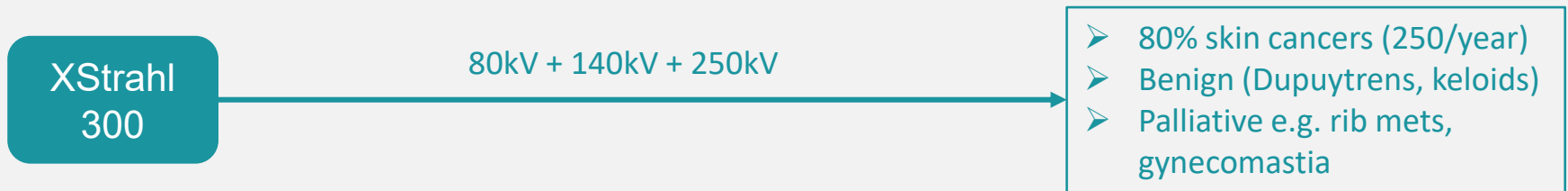
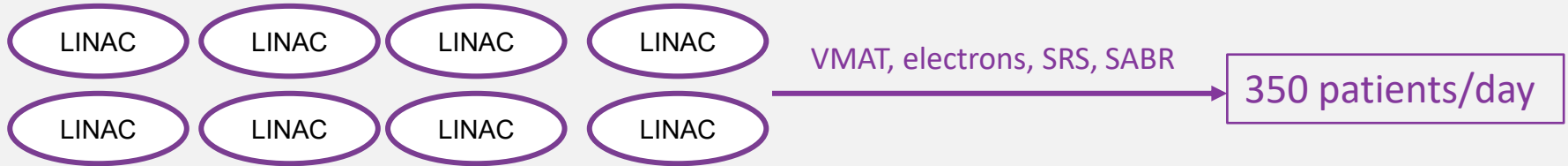
# Typical Mixed Model: RSCH, UK (2019)

73% of UK centres have at least one orthovoltage RT machine (Palmer BJR 2016)

*Royal Surrey Catchment*  
Population = 1.3 million

*Radiotherapy referrals*

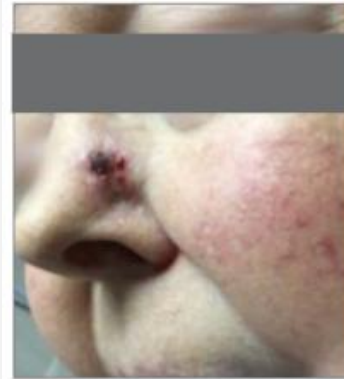- Total 3000 new patients per year
- > 300 radiotherapy for skin cancer



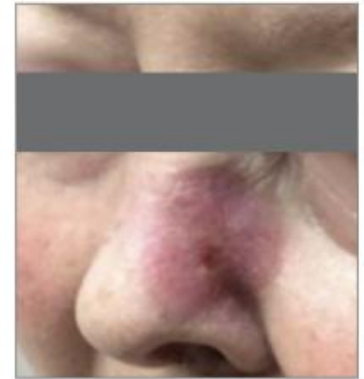# Case: SCC side of nose

## Tissue preserving

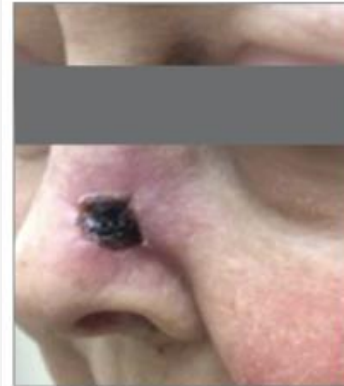- 69F
- DM, RA on immunosuppression, on anti-platelet therapy
- Multiple previous surgeries on face/scalp
- Treatment:
  - 52.5Gy in 15 fractions (3# per wk)
  - 80kV photons, 0.7cm margin



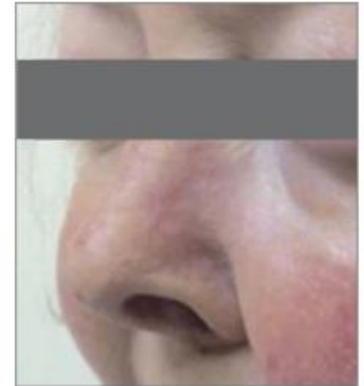*Biopsy*



*Final fraction*



*Two-weeks post-treatment*

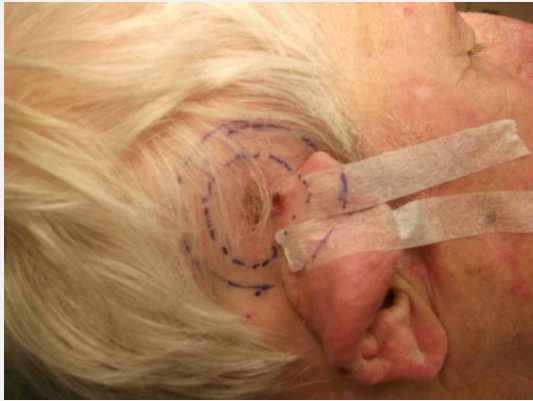

*One-month post-treatment*

# Cases: Ear and lip

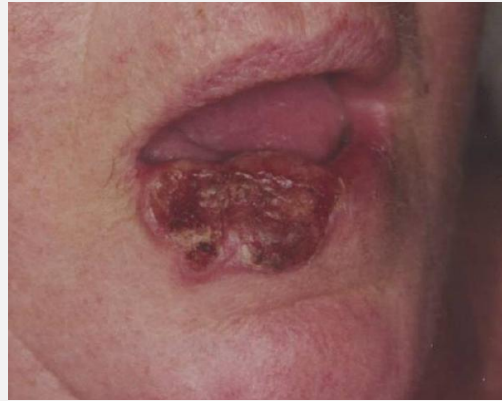## Tissue preserving

### Ear

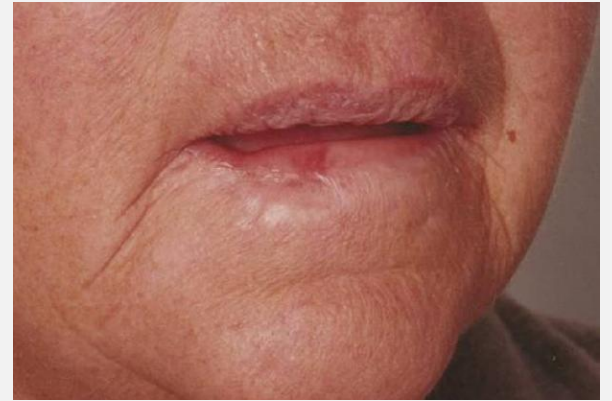

### Lip SCC

Pre-RT



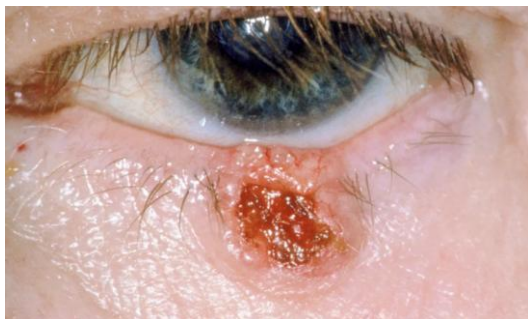6 months post-RT



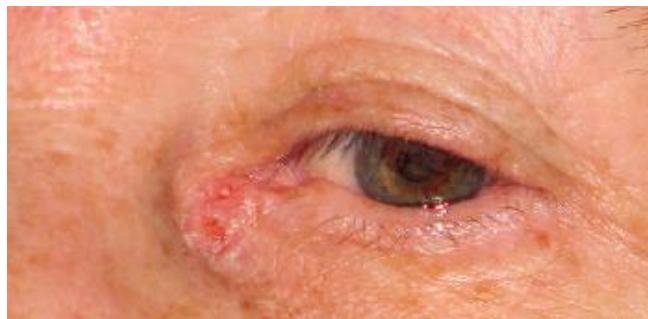
# Cases: Around the eye

## Tissue preserving, Eye protection, small fields

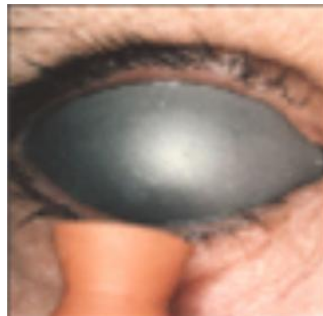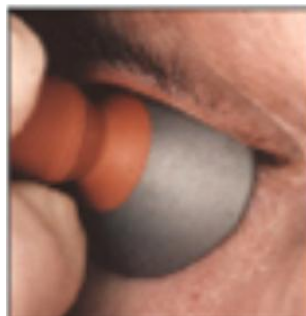
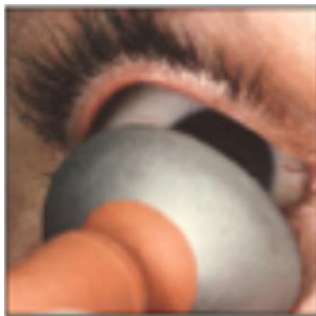Lower eyelid



Medial canthus



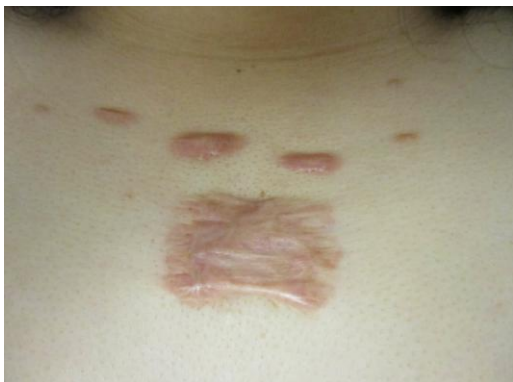Upper eyelid



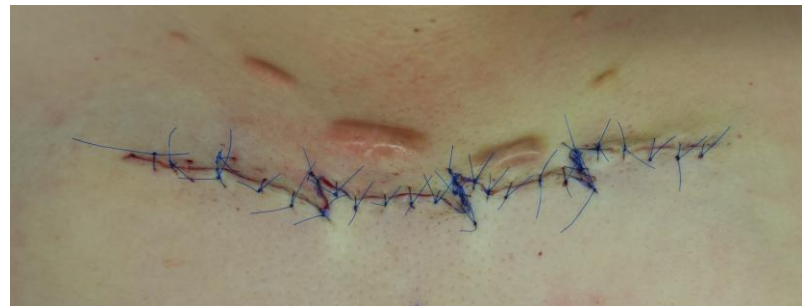# Keloid (high risk)

- 28F, pre-sternal keloid
- Treatment
  - Excision + z-plasty
  - PORT (48h post-excision)
  - 18Gy/3#/3d, 120kV photons

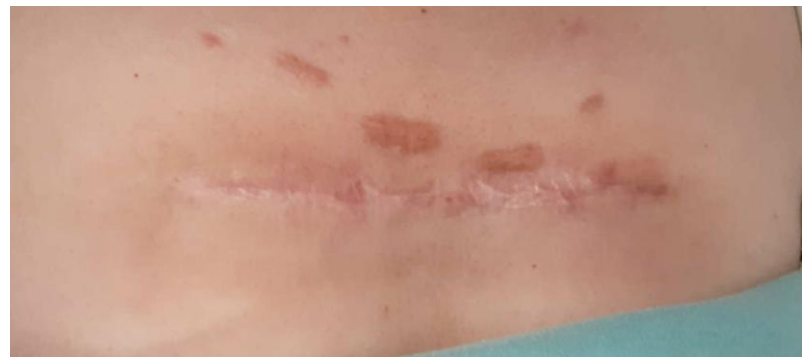Pre-op



Post-op



2 month follow-up



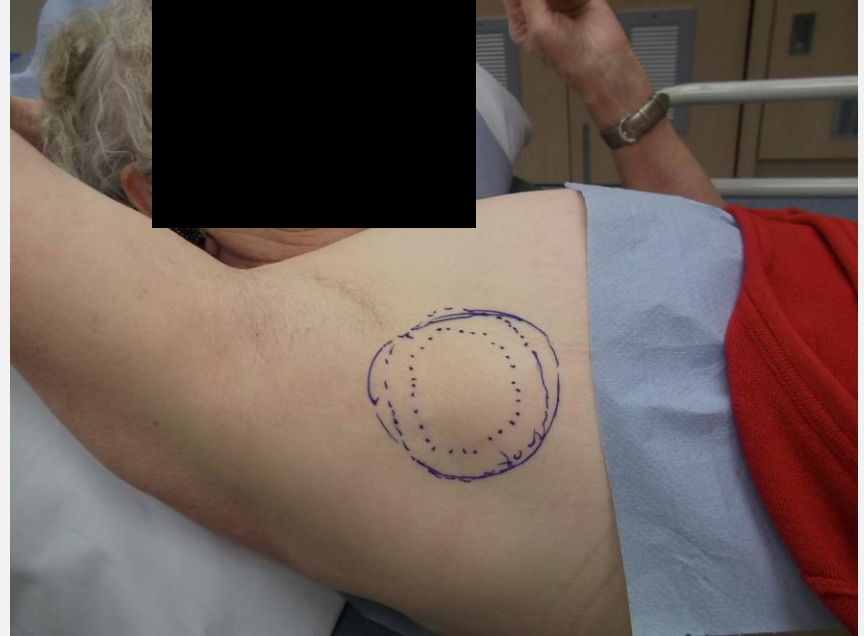# Palliative

- Superficial bone metastases e.g. ribs
- Skin metastases
- Gynecomastia

# Rib metastasis

## Frees up LINAC time

- 65 year old woman
- Ca splenic flexure
- Rib metastasis
- Treatment
  - 20Gy/5#, 300kV photons
- Good pain relief



# Benign Conditions

Groups	Dose
<b>Hyperproliferative</b> DD, LD, keloid	Intermediate
<b>Degenerative &amp; Inflammatory</b> Osteoarthritis, tendinopathy, bursitis	Low
<b>Inflammatory skin conditions</b> Psoriasis, eczema, DSAP	Low/intermediate
<b>Stereotactic</b> Intracranial, Cardiac	High dose per fraction
<b>Other</b> HO, Graves, PVNS, Sialorrhoea, Alzheimer's, HS	Various

# Benign MSK Conditions

## Shoulder

- M75.1 = Rotator cuff syndrome
- M75.2 = Bicipital tendinitis
- M75.3 = Calcific tendinitis of shoulder
- M75.4 = Impingement syndrome of shoulder
- M75.5 = Bursitis of shoulder
- M19.01 = Osteoarthritis, shoulder
- M75.9 = Shoulder lesion, unspecified

## Elbow

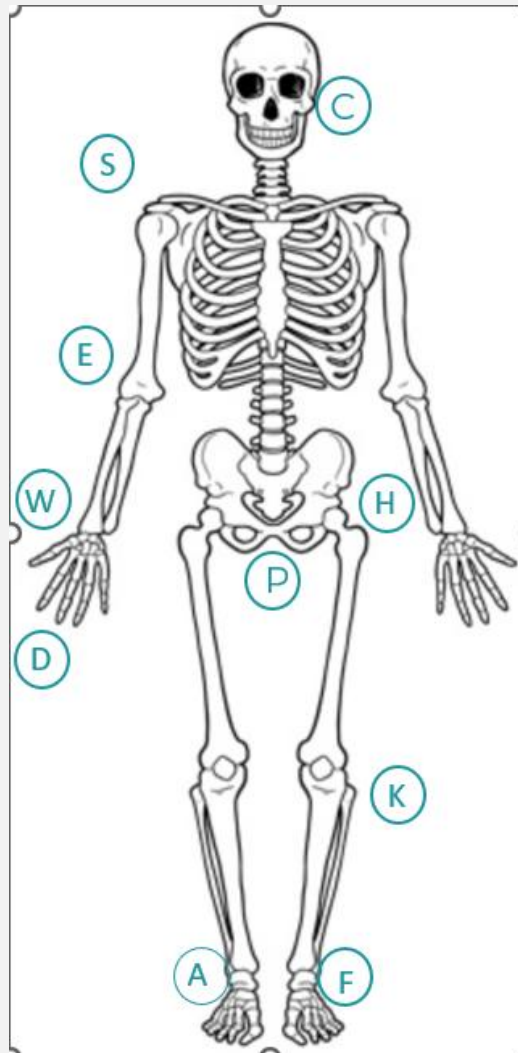
- M77.0 = Medial epicondylitis (Golfer's elbow)
- M77.1 = Lateral epicondylitis (Tennis elbow)
- M70.2 = Olecranon bursitis
- M19.02 = Osteoarthritis, elbow

## Wrist and Digits

- M72.0 = Dupuytren's disease
- M72.1 = Knuckle pads (Garrod)
- M15.9 = Osteoarthritis (OA) of fingers/wrist joints
- M18.9 = OA of CM1 joint (base of thumb)
- M65.4 = Radial styloid tenosynovitis [de Quervain]

## Other

- M19.9 = Osteoarthritis other location(s)
- M61.9 = Heterotopic ossification, Myositis Ossificans
- M12.2 = PVNS (pigmented villonodular synovitis)
- N62 = Gynecomastia



## Cranial

- M26.69 = TMJ OA

## Hip

- M70.6 = Trochanteric bursitis (GTPS)
- M16.9 – Coxarthrosis (= hip OA)
- M76.1 - Iliopsoas Tendinopathy
- M76.3 - Iliotibial band syndrome
- M53.3 – Coccyx pain
- M70.7 – Ischial bursitis

## Knee

- M17.9 = Knee Osteoarthritis
- M71.2 = Baker cyst
- M76.5 = Patellar tendinitis
- M70.4, M70.5 = Bursitis (pre-patellar, other)
- M94.2 = Diffuse chondromatosis

## Foot and Ankle

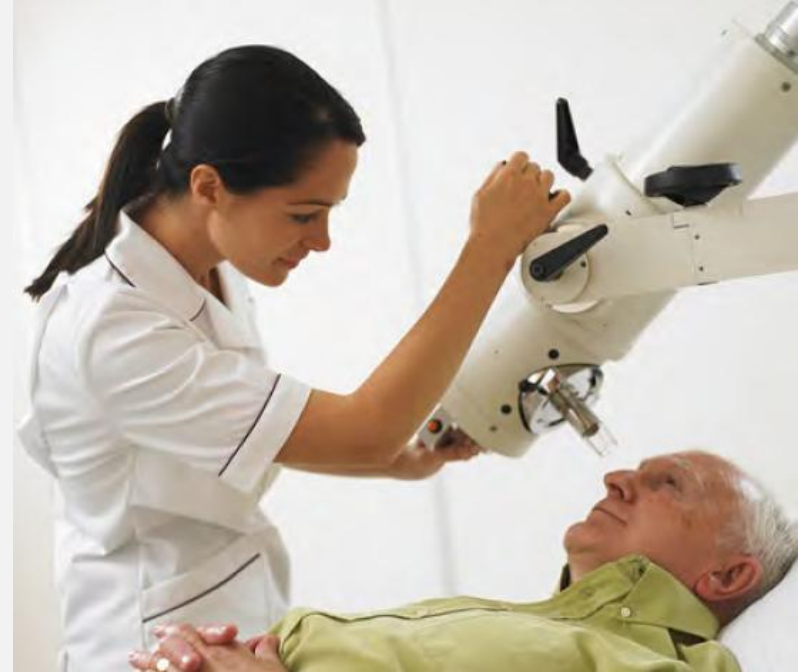- M72.2 = Plantar fascial fibromatosis
- M72.2 = Plantar fasciitis
- M76.6 = Achilles tendinitis
- M19.07 = Osteoarthritis of ankle and foot
- M20.2 = Hallux rigidus
- M76.8 = Other enthesopathies of lower limb, excluding foot
  - Anterior tibial syndrome
  - Posterior tibial tendinitis

## Penis

- N48.6 = Induratio penis plastica (Peyronie's disease)

# Superficial-Orthovoltage Radiotherapy - Summary

- Advantages
  - Value
  - Comfort
  - Simple clinical pathway
- Flexible
  - Freestanding
  - Part of multimodality department
- Versatile
  - NMSC, benign, palliative





**Thank you**

Dr Richard Shaffer

[Linkedin.com/in/dr-Richard-Shaffer](https://www.linkedin.com/in/dr-Richard-Shaffer)